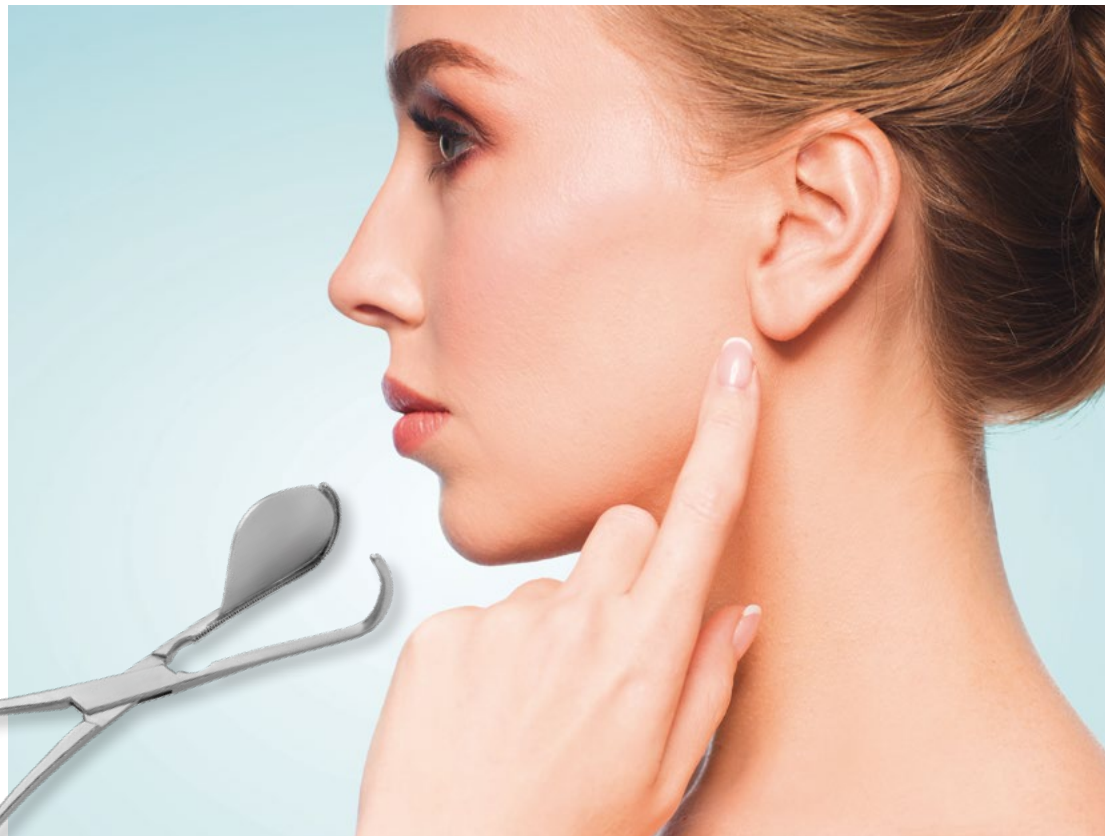
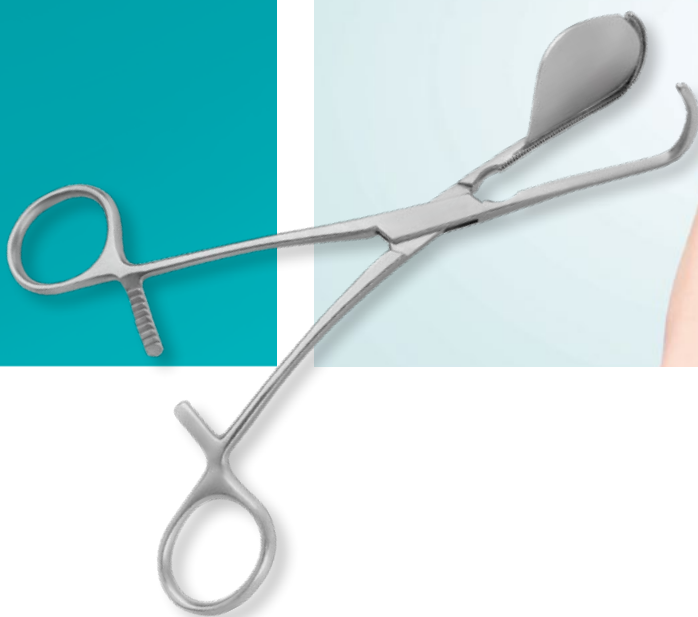
Earlobe  
Correction Forceps  
type Dr. Lotter



## USAGE



Torn or split earlobes are usually caused by inappropriately placed ear holes with little distance to the edge of the earlobe, by wearing heavy large gauge earrings or by tear injuries. Often both sides are affected. Besides that, several earring holes close together can be involved.

Furthermore, there is an increasing demand for the so-called flesh tunnel or ear tunnel repair. In this case extremely stretched earlobes should be put back into the aesthetic original. The procedure is performed under ear block anesthesia. This enables the preservation of normal tissue consistency without swelling and facilitates the stepless alignment of the wound edges.

After placing stay sutures the earlobe correction forceps according to Dr. Lotter should be placed in a way that, if possible, no cartilage areas of the ear will be squeezed. Coming from the direction of the earlobe the metal plate of the clamp is placed medial (towards the body) and the jaw without metal plate is laterally (away from the body). The jaws have an atraumatic serration which prevents them from slipping off the ear skin. Initially, only a few ratchets of the locking mechanism should be closed to allow bloodless surgery and to minimize the trauma of the tissue at the same time. After skin incision of the wound edges on each side the clamp should be opened to enable appropriate hemostasis. After that the wound can be closed.

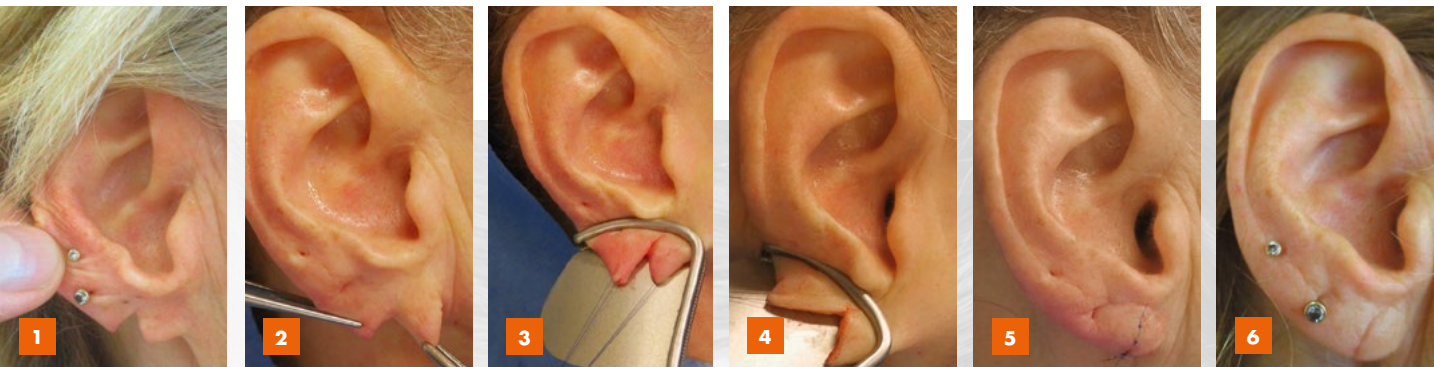
The earlobe correction forceps type Dr. Lotter offer an easier approach to surgeries on the earlobe. Besides the bloodless situs due to the atraumatic serration, the posterior metal blade of the forceps enables very good tissue resistance for working with the scalpel blade. Due to the length and weight of the instrument the earlobe stays in a correct and stable position for the surgeon.



### **ADJ. PROF. DR. MED. OLIVER LOTTER, MBA**

Head Physician at Clinic for Plastic,  
Aesthetic, Hand and Reconstruction Surgery  
Gesundheitszentrum Spaichingen  
Klinikum Landkreis Tuttlingen





- 1 Pre-surgery findings
- 2 Epithelialized parts of the divided earlobe
- 3 Stay sutures at the skin tips and placing of the earlobe correction forceps
- 4 De-epithelializing of the earlobe parts and refreshing of the wound edges
- 5 Result after skin closure
- 6 Result 6 weeks post-surgery



Earlobe Correction Forceps  
Atraumatic serration, 38 x 35mm blade (L x H)  
170mm, 6<sup>2</sup>/<sub>3</sub>" 410-901-000

Registered Design  
and Utility Model



## RZ Medizintechnik GmbH

Unter Hasslen 20  
78532 Tuttlingen, Germany

Phone: +49 (0)7462/9470-0  
Fax: +49 (0)7462/9470-50

[sales@rz-medizintechnik.com](mailto:sales@rz-medizintechnik.com)  
[www.rz-medizintechnik.com](http://www.rz-medizintechnik.com)

